

Case Report

A Stab Wound of Occipital Region of Skull, Simple in Nature: A Unique Case

Garg V.^{1*}, Simatwal N.², Sharma D.K.², Shaikh I.², Vyas P.C.²

¹Department of Forensic Medicine and Toxicology, Government Medical College, Kota, Rajasthan, India.

²Dr. S.N. Medical College, Jodhpur, India.

Correspondence Address: * Dr. Vinod Kumar Garg, Department of Forensic Medicine and Toxicology, Government Medical College, Kota, Rajasthan, India.

Abstract

Stab wounds are produced by pointed instruments. But in this case stab wound on the sub-occipital region of the skull on the left side, 12 cm deep and did not disturb any vital structure. All parameters were within normal range. Finally the injury was simple in nature & weapon was pointed sharp.

Keywords: Sub-occipital region, Kitchen knife, Simple injury

Introduction

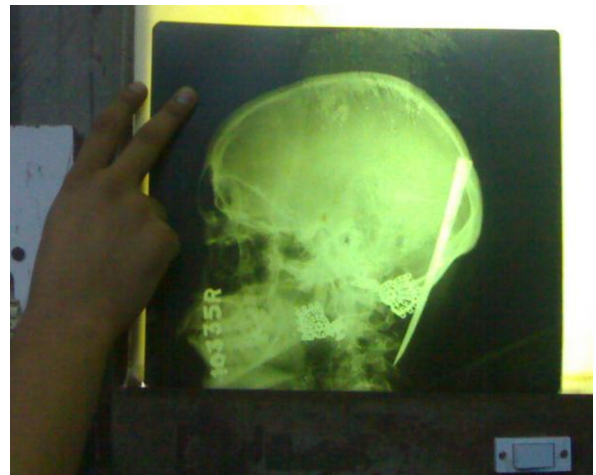- Stab wounds are produced by pointed instruments. Most are homicidal. In stab wounds, the depth of the wound track in the body exceeds its length in the skin.¹
- It is the depth of the injury that makes it so often fatal and hence of such forensic interest.²
- Even a puncture by pin or needle in nape of neck can cause fatal outcome.³
- But in this case stab wound on the sub-occipital region of the skull on the left side, 12 cm deep and did not disturb any vital structure.
- Such type of stab wound was not reported here before.

Case report

- A 30-year-old married female having two children, was at home with her husband on 7th august 2010. At night, about 10 pm husband got angry on wife on some

matter. He attacked on his wife with kitchen knife.

- The knife entered in the sub-occipital region of the skull. On crying of children, the neighbours brought the female in the emergency at 11.30pm with complaint of bleeding from scalp with knife blade in-situ.



X-ray (lateral view): prior to removal of blade

Observation

- Patient was conscious, oriented to time, place and person.
- General physical examination –normal.
- Vitals -
B.P.-130/80 mm of Hg,
P-100/min,
R.R.- 18/min.,
SpO₂-98%.

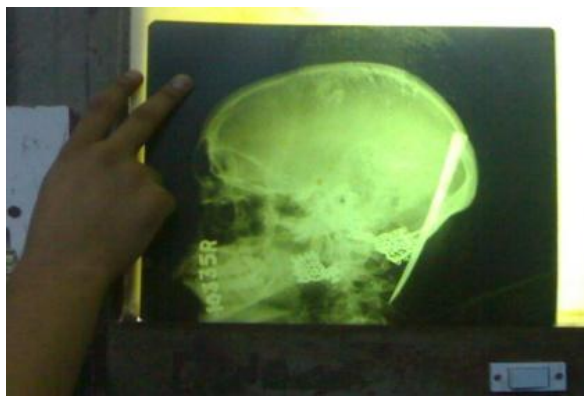
Injury Report

Stab wound of size 1.5x0.5cm with contused margins was obliquely placed over left side sub occipital region laterally and 5cm posterior to left ear pinna with blade in-situ & pouring of blood. Diffuse swelling was present on the left side of sub-occipital region.

- Nature of injury- opinion was reserved for-
 - a) X-ray skull -anterior-posterior & lateral view
 - b) surgical notes
 - c) treatment record
 - d) complete healing.
- The kind of weapon was pointed sharp.

a) X-ray report

- There was no fracture of cervical vertebrae.



X-ray: No fracture of cervical vertebrae

b) Operative notes

- Knife blade was removed under general anesthesia. The knife blade caught by artery forceps & removed.

- Stab wound was cleaned & pressure dressing done over the stab track.
- The length of blade was 12 cm & single edged.
- The vitals were stable during the operative procedure.

(c) Treatment record

The patient discharged was discharged without any symptoms & complications.. During admission the vitals & other parameters were stable.

According to neurosurgeon there was no neurological deficit.

The reports of investigations→

- A) Blood sugar-95mg/dl
- B) Blood urea-30mg/dl
- C) Serum creatinine-1.10mg/dl
- D) Urine report-albumin, sugar, cast, pus cells -Nil
- E) CBC- Hb-10gm/dl,
- F) TPR charting was normal during hospital stay.

d) Complete healing

- Patient was reviewed after complete healing.
- No restriction of neck movements seen after review.

Final Opinion

After taking consideration the x-ray report, operative notes, treatment record and review report the injury was simple in nature.

Discussion

- As mentioned before, this is the first reported case here of a 12 cm deep stab wound of sub-occipital region without any sensory-motor loss.
- A patient who was stabbed in the back of his neck with a knife and who later presented with a brown-séquad syndrome attributable to cervical spinal cord damage. Myelography and CT revealed a compressive extradural lesion shown at exploratory operation to be a

loculus of cerebrospinal fluid (CSF). The loculus had formed as a consequence of leakage of CSF.⁴

- A case of partial spinal cord transection due to a stab wound to the neck. It resulted in priapism.⁵
- Unlike present case, both above cases had neural symptoms.
- The back of neck is supplied by the c2,c3,c4 nerve and occipital artery.⁶
- The knife blade did not injure the medulla, spinal cord, and nerves. Because in present case the knife blade entered in the muscle layer of left sub-occipital region.

Conclusion

- Not always, all stab wounds in vital part are dangerous to life. Before giving the final opinion, a medico legal expert should observe the all facts about the injury before giving the final opinion.
- Finally, in this case, the nature of injury was simple but weapon was dangerous.

References

1. Vincent J. DiMaio, Dominick DiMaio. Forensic Pathology: Second Edition 'Wounds Caused by Pointed and Sharp-Edged Weapons' page-202.
2. Simpson's Forensic Medicine Twelfth Edition: 'The Examination of Wounds' page-65.
3. Reddy (2010), 'the essentials of forensic medicine and toxicology' 29th edition, page-182.
4. R.D. Page & R.H. Lye. 'Stab wound of neck: potential pitfalls in management' archives of emergency medicine, 1989, 6, 225-229.
5. Al-janabi, T.; Nayeem, N.; Smallman, 'Stab wound to the neck-a rare presentation' European Journal of Emergency Medicine: March 2001 - Volume 8 - Issue 1 - pp 55-56.
6. B.D. Chaurasia's Human Anatomy, 4th Edition 'Head, Neck And Brain' page-77-79.