

Management of PUJ obstruction

Chugh A.*, Agarwal P.N., Singh R., Mishra A., Jain V., Meena M.

Dept of General Surgery, MAMC.

Correspondence Address: * Anmol Chugh, Dept of General Surgery, MAMC.

Abstract

Pelvi--ureteric junction (PUJ) obstruction is a well-recognized entity that may present at any time – in fetal life, infancy, childhood, or early or late adulthood. As the most common site of obstruction in the upper urinary tract. There has been an improved understanding of the pathophysiology of primary congenital PUJ obstruction that has been reflected in the evolution of surgical options, from open surgical repair to minimally invasive surgery. This article discusses the surgical management of this condition alongwith the pathogenesis, clinical presentation, and diagnosis of PUJ obstruction.

Keywords: Kidney, Kidney pelvis, Ureteral obstruction, Surgery, Percutaneous

Introduction

PUJ obstruction is defined as an obstruction of flow of urine from the renal pelvis to the ureter. Most cases are congenital, but it may not become clinically apparent until much later in life.

The incidence of PUJ obstruction is less well defined in adults than in children. In the paediatric age group, it is the most common cause of upper urinary tract dilation. The male-to-female predominance is greater than 2:1, and the left kidney is affected about twice as often as the right.¹ PUJ obstruction occurs in adults less frequently than in neonates.

Etiology

PUJ obstruction from congenital causes may result from either an anatomic or a physiologic defect in the upper ureter.

- Primary luminal narrowing caused by an incomplete recanalization process in

utero at the cephalad end of the developing ureter.

- Presence of an aperistaltic segment of the ureter. Histopathologic studies reveal the replacement of spiral musculature by abnormal longitudinal muscle bundles, thus normal peristaltic wave cannot be generated for flow of urine.²
- Cytokine produced in the urothelium, transforming growth factor- β , epidermal growth factor expression, nitric oxide, and neuropeptide Y have also been found as cause of PUJ obstruction.³
- Ureteral kinks or valves produced by infoldings of the ureteral mucosa and musculature may also cause obstruction.
- Abnormal insertion of the ureter results in high-insertion PUJ obstruction.
- Crossing vessels compressing or distorting the PUJ may cause ureteral outflow obstruction.⁴

Classification of antenatal hydronephrosis, based on renal pelvic anteroposterior diameter

	Second trimester	Third trimester
Mild	4-6 mm	7-9 mm
Moderate	7-10 mm	10-15 mm
Severe	>10 mm	>15 mm

- Secondary causes can be due to upper tract infection, stones, trauma (eg, instrumentation) which can cause reactive fibrosis and formation of stricture.

Presentation

PUJ obstruction can present at any time of life. Initial presentation in neonates and infants can be a palpable flank mass. Use of antenatal USG has resulted in increase in number of patients diagnosed with hydronephrosis.

In older children or adults, intermittent abdominal or flank pain, at times associated with nausea or vomiting, is a frequent presenting symptom. A detailed history may reveal that the pain correlates with periods of increased fluid intake associated with swelling in loin which disappears when large amount of urine is passed (Dietl’s crisis). Findings of microhematuria, pyuria, or frank urinary tract infection may be present.

Diagnosis

Goal- To determine both the anatomic site and the functional significance of an apparent obstruction.

1. Ultrasonography (USG) is the initial diagnostic study. It visualizes dilatation of the collecting system & determine the level of obstruction. Parenchymal thickness, degree of hydronephrosis, status of opposite kidney and presence of stones can be diagnosed with accuracy.

- **Antenatal USG:** Detection of antenatal hydronephrosis (ANH) by ultrasound usually occurs in the second trimester with a renal pelvic dilation (RPD) cutoff of greater than or equal to 4 mm. ANH is present if fetal renal antero-posterior diameter (APD) is ≥ 4 mm in the second trimester and ≥ 7 mm in third trimester.⁵

If fetal hydronephrosis is detected, the following parameters are evaluated:

1. Severity of hydronephrosis: The likelihood of a congenital kidney or urinary tract anomaly increases with the severity of RPD.
2. Unilateral versus bilateral involvement: Bilateral involvement increases the risk of a significant renal abnormality and the risk of impaired postnatal renal function.

- **Postnatal USG:** The timing depends on the severity of antenatal hydronephrosis and whether there is bilateral involvement or an affected solitary kidney. Examination is avoided in the first 2 days after birth because hydronephrosis may not be detected because of extracellular fluid shifts that underestimate the degree of hydronephrosis. However, in infants with bilateral hydronephrosis and those with a severe hydronephrotic solitary kidney, urgent evaluation on the first postnatal day is done because of the increased likelihood of significant disease and possible need for early intervention. For unilateral hydronephrosis without antenatal bladder pathology, performing postnatal sonography 1-4 weeks after birth is recommended.⁵

Advantages and disadvantages

The main advantages are ease of use, ability to detect other causes of renal disease like

polycystic kidney disease, non-invasive, lack of radiation and contrast, low cost & easy availability. Disadvantages are dependence on operator skills and non-assessment of functional status of kidney.

2. **Excretory urography** remains a good option for radiographic diagnosis after USG. Kidney function test should be normal for the test to be done. Classical findings are, delay in function on affected side associated with a dilated pelvicalyceal system. If the ureter is visualized, it is of normal caliber. It assesses function in obstructed kidney and delineates anatomy.
3. **Diuretic renography** measures the drainage time from the renal pelvis and assesses total and individual kidney renal function. It is the best test to establish that dilation of the renal collecting system is due to obstruction. A substance (DTPA or MAG-3) that is filtered by glomeruli and not absorbed is given intravenously. ^{99m}Tc -MAG3 is the preferred isotope because of favourable imaging and dosimetry considerations over ^{99m}Tc -DTPA. Diuretic is given 20 minutes into the study to allow time for filling of the collecting system.⁶

Functionally significant obstruction is often diagnosed with diuretic renal scanning with non washout of isotope even after Lasix. Poorly functioning kidneys (< 10%) are often best treated with nephrectomy.

Advantages and disadvantages

The benefits are that iodine-based intravenous contrast is not used, radiation exposure is minimal, and renal function can be better quantified. The disadvantage is that insight into renal anatomy is not obtained.

4. **Dynamic pressure perfusion studies** done in cases with equivocal diuretic renograph, that is inability to

differentiate obstructive from non-obstructed dilated system by placing a percutaneous nephrostomy tube. First described by Whitaker in 1973, the renal pelvis is continuously perfused at 10mL/min with normal saline solution or dilute radiographic contrast solution under fluoroscopic control. Renal pelvic pressure is monitored during the infusion, and the pressure gradient across the PUJ is determined. During the infusion, the bladder is continuously drained with an indwelling catheter to prevent transmission of intravesical pressures. Renal pelvic pressure ranging up to 15 to 22 cm H₂O are highly suggestive of a functional obstruction.

5. **Helical CT angiography** may be used to help establish the anatomy of PUJ obstruction and associated vessels.⁷ It is not routinely indicated.
6. **MR Urography** offers the advantages of no radiation exposure and excellent anatomical and functional details with a single study, especially in children. The study also provides details of renal vasculature, renal pelvis anatomy, location of crossing vessels, renal cortical scarring, and ureteral fetal folds in the proximal ureter.
7. **Endoluminal ultrasonography** is a technique in which small-diameter (6F) sonographic probes are placed in the ureter, usually at the same time as endopyelotomy, to evaluate the nature of the PUJ obstruction and to localize any adjacent vasculature before endoscopic incision. On compared with HCTA (35%), it was found that endoluminal ultrasonography identified more crossing vessels in patients with PUJ obstruction (70%).⁸ It can identify both arteries and veins. It can approximate vessel size and determine the dynamic location of vessels with respirations. It

may be employed immediately before endopyelotomy to delineate the dynamic location of vessels that can change with respirations, thus facilitating the proper placement, depth, and length of endopyelotomy incision.

Surgical intervention

Indications for intervention are:

- Hydronephrosis
- Bouts of renal colic
- Evidence of parenchymal damage
- Development of infection

(A) Open operative intervention

Aim of repair

- To create a widely patent and funnel shaped uretero-pelvic junction of adequate caliber.
- Dependent drainage
- Watertight anastomosis
- Tension-free anastomosis
- Adequate vascular supply

Dismembered pyeloplasty

Preferred because it is applicable to the different clinical scenarios.

- Can be used if ureteral insertion is high on the pelvis or already dependent.
- Permits reduction of a redundant pelvis or straightening of a tortuous proximal ureter.

- Anterior or posterior transposition of the PUJ can be done in obstruction due to accessory or aberrant lower pole vessels.
- It is not suited to a PUJ Obstruction due to multiple or lengthy proximal ureteral strictures or patients with a small intrarenal pelvis.

Method

The proximal ureter is dissected cephalad to the renal pelvis, leaving a large amount of periureteral tissue to preserve the ureteral blood supply. Below the level of the obstruction, a suture is placed on the lateral aspect of the proximal ureter to orient for the subsequent repair. Medial and lateral aspects of the dependent portion of the renal pelvis are marked with traction sutures. The PUJ tissue is excised, and the proximal ureter is then spatulated on its lateral aspect. The apex of this lateral, spatulated aspect of the proximal ureter is brought to the inferior border of the renal pelvis, whereas the medial side of the ureter is brought to the superior aspect.⁹The anastomosis is of ureteral and renal pelvic wall is done in a watertight manner. Anastomosis over an internal stent is done, which is left in situ.

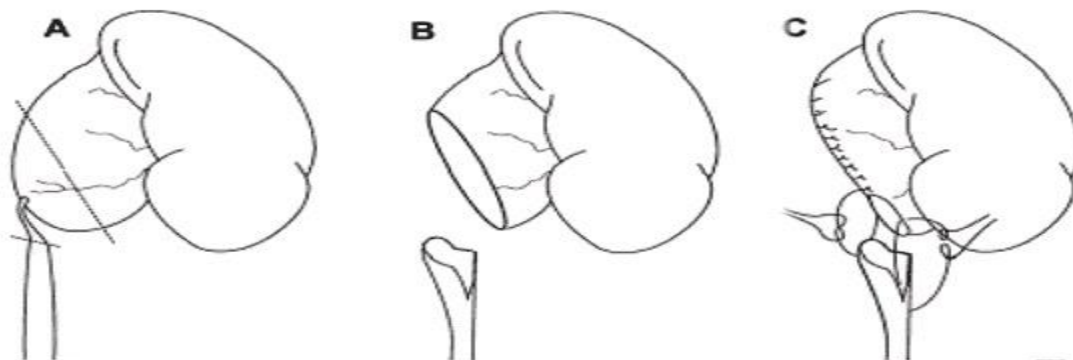


Fig. 1: Dismembered pyeloplasty

In redundant renal pelvis, a “reduction” pyeloplasty can be performed by excising the redundant portion of the pelvis. The cephalad aspect of the pelvis is closed with running absorbable sutures down to the dependent portion and then to the ureter.⁹ It allows transposition of the PUJ in relation to aberrant vessels.

Advantages

- Good exposure of PUJ
- Ability to tailor renal pelvis
- Watertight anastomosis
- Familiar anatomy for all surgeons

Disadvantages

- Large surgical incision
- Post-operative pain and recovery time more

Flap procedures

- Can be combined with dismembered pyeloplasty in a dilated extra renal pelvis.
- Creates more funnel shaped PUJ.
- Useful in cases with dependent PUJ despite significant pelvic dilation.
- Interferes less with ureteral blood supply.
- Useful in PUJ obstruction in horse-shoe/pelvic kidney

FOLEY Y-V PLASTY

- Originally designed for repair of a PUJ obstruction secondary to a high ureteral insertion.¹⁰
- Generally been replaced by dismembered pyeloplasty
- Contraindicated when transposition of lower pole vessels is necessary

Method

CULP-DE WEERD SPIRAL FLAP

- For large, easily accessible extrarenal pelvis in which the ureteral insertion is already in a dependent, oblique position.
- Useful when both PUJ Obstruction and a relatively long segment of proximal ureteral narrowing or stricture occur in the same setting.

Method

SCARDINO-PRINCE VERTICAL FLAP

- Used only when dependent UPJ Is situated at the medial margin of a large, square (“box-shaped”) extrarenal pelvis

The vertical flap technique cannot produce as long a flap as the spiral flap.

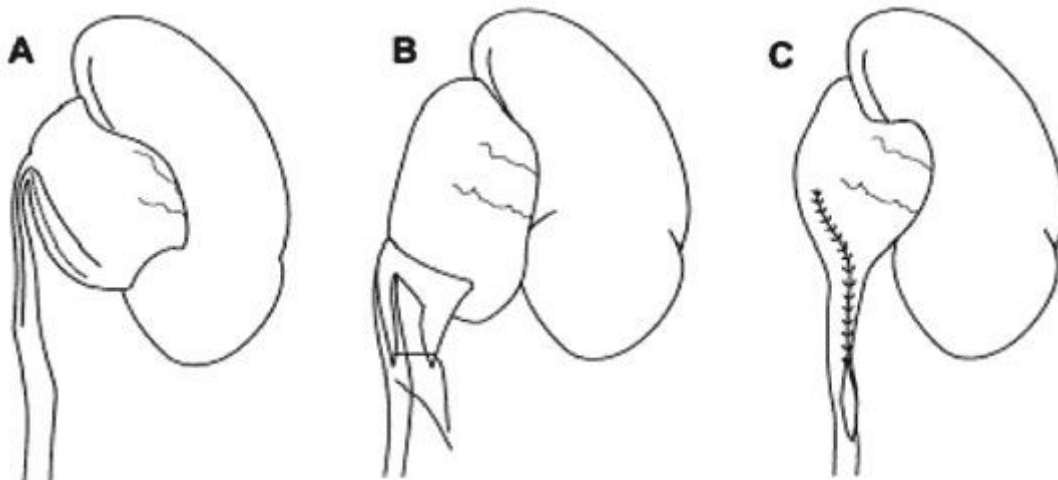


Fig. 2: Foley Y-V plasty

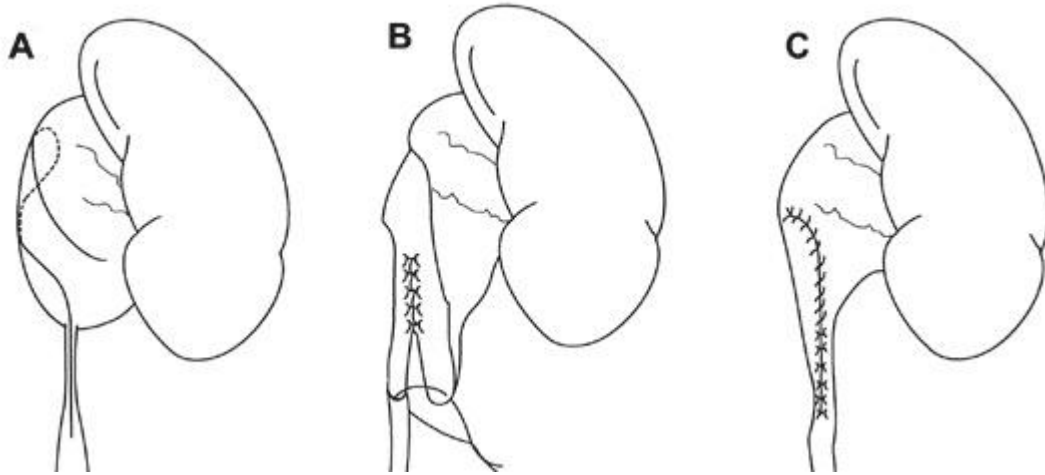


Fig. 3: Spiral Flap

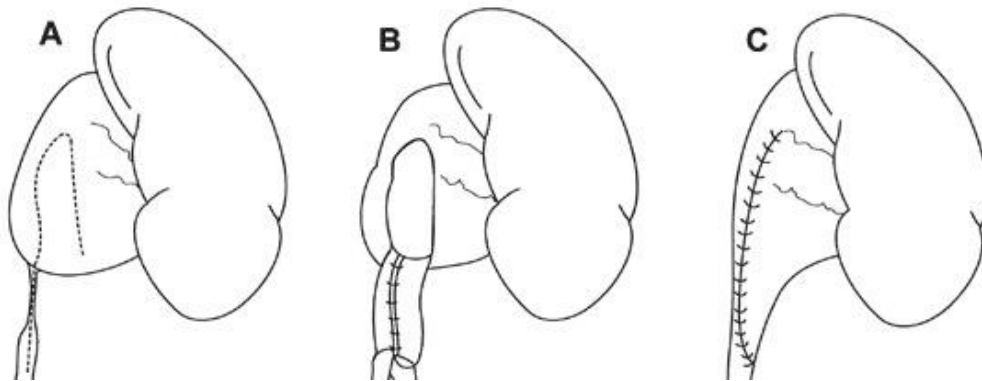


Fig. 4: Vertical Flap

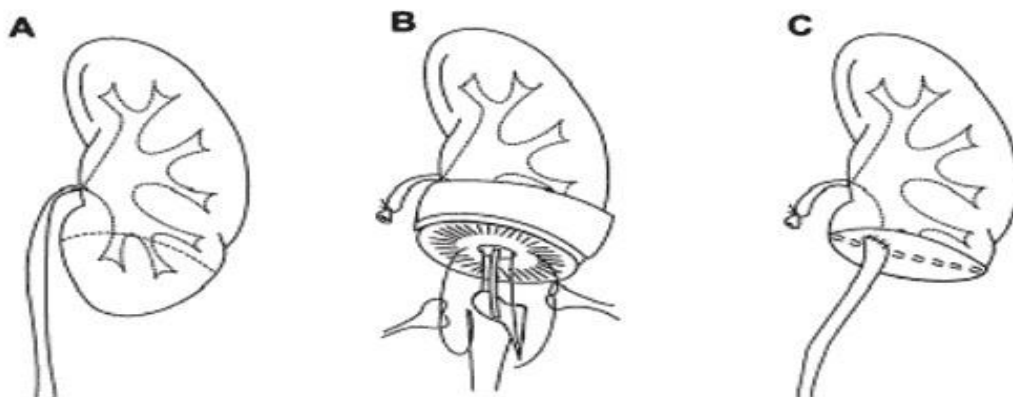

Fig. 5: Ureterocalycostomy

Method

URETEROCALYCOSTOMY

- Used as primary reconstructive procedure whenever a PUJ obstruction or proximal

ureteral stricture is associated with a relatively small intrarenal pelvis.

- When the PUJ is associated with rotational anomalies such as horseshoe kidney.

- Well accepted salvage technique for the failed pyeloplasty.

(B) Endourologic management

Open operative intervention for PUJ obstruction with 95% success rate provides a widely patent, dependently positioned, well-funnelled PUJ. Several less invasive alternatives to standard operative reconstruction are now available. The advantages of endourologic approaches include a significantly reduced hospital stay and postoperative recovery. However open, laparoscopic, or robotic pyeloplasty can be applied to almost any anatomic variation of PUJ obstruction and taking into account the degree of hydronephrosis, ipsilateral renal function, concomitant calculi, and possibly the presence of crossing vessels.

A full thickness incision is made laterally through the obstructing proximal ureter, from the ureteral lumen out to the peripelvic and periureteral fat to avoid any crossing vessels. The incision is then left to heal over a double J stent. More recently, the procedure has been undertaken using a hot knife or Holmium laser. Endopyelotomy can also be performed ureteroscopically in retrograde manner. Whichever approach is adopted, initial access across the obstructing pelviureteric junction is required for a safe endopyelotomy to be performed.

Percutaneous antegrade endopyelotomy

With several alternative minimally invasive options available including laparoscopy, a percutaneous approach is most appropriate for those patients with concomitant pyelocalyceal stones, which can then be managed simultaneously. Contraindications to a percutaneous endopyelotomy are similar to the contraindications to any endourologic approach and include a long segment (> 2 cm) of obstruction, active infection, or untreated coagulopathy.¹¹ Mere presence of crossing vessels is not a contraindication to an endopyelotomy. However, significant entanglement of the PUJ by crossing vessels

can occasionally be identified and this may render any endourologic approach unsuccessful.

Complications

- Haemorrhage
- Infection

Studies

- A study by Van Cangh and colleagues found that the presence of a crossing vessel lead to a lower success rate with endopyelotomy compared to the absence of a crossing vessel (42% vs 86%)¹²
- Kapoor and colleagues found a lower success rate (62% vs 90%) for patient with poor renal function (GFR = 5-15ml/min) who underwent antegrade endopyelotomy, as compared to patients with better renal function (GFR>15ml/min).¹³
- Biyani and colleagues found patients with mild to moderate hydronephrosis have higher success rates compared to those with severe hydronephrosis.¹⁴

The presence of a crossing vessel, preoperative differential split renal function < 30%, PUJ obstruction >2 cm and moderate to severe HDN are associated with a poor prognosis with primary endopyelotomy, and laproscopicpyeloplasty as first-line treatment should be done.

Endopyelotomy is a less invasive procedure with a shorter operative time and can be useful for pts with significant medical comorbidities or contraindications to laparoscopy. Finally, endopyelotomy is the treatment of choice for failed pyeloplasty and concomitant renal calculi.

(C) Laparoscopic pyeloplasty

Laparoscopicpyeloplastyhaslower patient morbidity, shorter hospitalization, and faster convalescence, with the reported success rates matching those of open pyeloplasty (≥90%).Following the similar surgical

principles of anatomic dissection and repair used in open pyeloplasty, laparoscopic pyeloplasty has been shown to provide the success rates surpassing those of endopyelotomy by approximately 10% to 30%.¹⁵

It can be performed by either retroperitoneal or transperitoneal approach. Various techniques can be divided into dismembered and non-dismembered techniques. The dismembered or Anderson-Hynes technique involves division of the PUJ and excision of the narrowed segment, followed by reanastomosis of the ureter to the renal pelvis. Non-dismembered techniques are Foley Y-V plasty and Fenger pyeloplasty

Contraindications:

- Uncorrected coagulopathy
- Active UTI
- Cardiopulmonary compromise
- Bleeding diathesis

(D) Robotic-assisted laparoscopic approach

The most widely used robotic system is the da Vinci Robot (Intuitive Surgical, Sunnyvale, CA), with the reported benefits of enhanced three-dimensional vision, motion scaling, tremor reduction, improved dexterity, and increased range of motion. Procedure is performed in a transperitoneal manner providing a larger working space for the robotic arms, although the feasibility of retroperitoneal approach has been recently demonstrated in a small number of patients.¹⁶ Ureteral stent may be placed via a cystoscopic retrograde or laparoscopic antegrade manner.

In both transperitoneal and retroperitoneal approaches, at least four different trocars are used in a robotic-assisted procedure including three for the robotic arms and one for the surgical assistant to perform suction, irrigation, retraction, and suture introduction. Following the initial laparoscopic access and trocar placement, the robotic system is placed in close

proximity to the operating table and the robotic arms are attached to the laparoscope and specifically designed laparoscopic instruments. The surgeon at the console operates via the control of the robotic arms, while the assistant remains at the bedside and performs suction, retraction, exchange of laparoscopic instruments, suture needle introduction, and removal. The general surgical steps are identical to those for non-robotic-assisted laparoscopic pyeloplasty.¹⁷ Urinary leak is the only complication specific to the procedure.

Summary

Most studies define treatment “success” as resolution of both symptoms and hydronephrosis. Laparoscopic pyeloplasty yields success rates of 93% to 100%, equivalent to those of open pyeloplasty. Endopyelotomy is significantly less effective, with success rates varying according to the particular approach employed; 67% to 86% for antegrade endopyelotomy.¹⁵

The superior effectiveness of laparoscopic pyeloplasty over endopyelotomy becomes even more pronounced in the long-term. Dimarco and colleagues followed patients after laparoscopic pyeloplasty or endopyelotomy and the 3, 5, and 10 year recurrence-free survival rates were 85%, 80% and 75% for laparoscopic pyeloplasty and only 63%, 55%, and 41% for endopyelotomy, respectively.¹⁸

The 5 year mean success rate of antegrade endopyelotomy is only 42% in the presence of a crossing vessel. Laparoscopic pyeloplasty, unlike endopyelotomy, allows for transposition of crossing vessels from anterior to posterior or vice versa with a 90% success rate.¹⁸

Complications of laparoscopic pyeloplasty include urinary leak, UTI, stent migration and haemorrhage requiring transfusion. Reported complication rates are 0-18% with most series citing about 10%.¹⁵

Complications of endopyelotomy include haemorrhage requiring transfusion, ureteral avulsion, stricture. Complication rates range from 0-42%. Comparable to laparoscopic pyeloplasty, endopyelotomy has complication rates of about 10%.¹⁸

Most failures from laparoscopic pyeloplasty occur in the first 2 years.¹⁹ If laparoscopic pyeloplasty fails, open surgery is used as a salvage procedure, with success rates of approximately 86%.²⁰ Endoscopic intervention such as endopyelotomy, with success rates of approximately 70% can also be used.²¹

In a study by Link et al comparing robotic and laparoscopic pyeloplasty in a prospective manner, the mean operative time and total room time for robotic cases were found to be significantly longer than laparoscopic cases by 19.5 and 39 minutes, respectively. With mean follow-up times of 11 to 39.1 months, the rates of surgical success are in the range of 94.7% to 100%. Robotic cases were also found to be more costly than laparoscopic cases (2.7 times) due to longer operative time, increased consumables costs, and depreciation of the robot system. In the hands of experienced laparoscopic surgeons, the use of the robot does not seem to provide significant clinical or cost advantage compared with conventional laparoscopic approach. In addition to cost, additional concerns for the robotic-assisted laparoscopic pyeloplasty include limited instrumentation and need for experienced bedside laparoscopic assistance.²²

No prospective randomized trial has been successfully completed to compare laparoscopic with open pyeloplasty to date because of the unwillingness of the patients to undergo randomization due to the different levels of perceived invasiveness. In a retrospective study, Bauer and colleagues (1999) compared 42 laparoscopic pyeloplasties and 35 open pyeloplasties. With a minimum follow-up of 12 months for each of the patients, the two groups were

found to be equivalent in pain relief (90% vs. 91%, respectively) and relief of obstruction (98% vs. 94%, respectively).²³ In another retrospective study, Soulie and colleagues examined 26 laparoscopic pyeloplasties and 28 open pyeloplasties (Soulie et al, 2001). The two groups were found to be equivalent in mean operating time (165 vs. 145 minutes, respectively); mean blood loss (92 mL vs. 84 mL, respectively); perioperative complication rate (11.5% vs. 14.3%, respectively); mean hospital stay (4.5 days vs. 5.5 days, respectively); and radiologic success (89% vs. 89%, respectively). However, more laparoscopic patients were found to have returned to normal activity by postoperative day 15 (90% vs. 70%, respectively).²⁴

References

1. Roth, Gonzales, 1983. Roth DR, Gonzales Jr ET: Management of ureteropelvic junction obstruction in infants. *J Urol* 1983; 129:108.
2. Koff SA et al: Pathophysiology of ureteropelvic junction obstruction: Experimental and clinical observations. *J Urol* 1986; 136(1, Pt 2):336-338.
3. Wang GJ et al: Factors disrupting smooth muscle investment of the ureter and ureteropelvic junction. *J Urol* 2009; 181(1):401-407.
4. Stephens, 1982. Stephens FD: Ureterovascular hydronephrosis and the "aberrant" renal vessels. *J Urol* 1982; 128:984.
5. Reddy PP, Mandell J: Prenatal diagnosis: Therapeutic implications. *Urol Clin North Am* 1998; 25:171.
6. Thrall JH et al: Diuretic radionuclide renography and scintigraphy in the differential diagnosis of hydronephrosis. *Semin Nucl Med* 1981; 11(2):89-104.
7. El-Nahas AR, Abou-El-Ghar M, Shoma AM, Eraky I, El-Kenawy MR, El-

- Kappany H. Role of multiphasic helical computed tomography in planning surgical treatment for pelvi-ureteric junction obstruction. *BJU Int.* Sep 2004;94(4):582-7.
8. Bagley DH, Liu JB. Endoluminal sonography to define the anatomy of the obstructed ureteropelvic junction. *UrolClin North Am.* May 1998;25(2):271-9.
 9. Smart WR: Surgical correction of hydronephrosis. In: Harrison JH(ed.) *Campbells Urology*, Vol. 3. Saunders, Philadelphia, 1979.
 10. Foley FEB: A new plastic operation for stricture at the ureteropelvic junction. *J Urol* 1937;38:643.
 11. Brannen, Bush, Lewis, 1988. Brannen GE, Bush WH, Lewis GP: Endopyelotomy for primary repair of ureteropelvic junction obstruction. *J Urol* 1988; 139:29.
 12. Van Cangh et al, 1994. Van Cangh PJ, Wilmart JF, Opsomer RJ, et al: Long-term results and late recurrence after endoureteropyelotomy: a critical analysis of prognostic factors. *J Urol* 1994; 151:934.
 13. Kapoor R, Mandhani et al: Is a 2-week duration sufficient for stenting in endopyelotomy?. *J Urol* 2003; 169:886.
 14. Biyani, Cornford, Powell, 1997. Biyani CS, Cornford PA, Powell CS: Retrograde endoureteropyelotomy with the holmium:YAG laser. Initial experience. *EurUrol* 1997; 32:471.
 15. Inagaki, Rha, Ong, 2005. Inagaki T, Rha KH, Ong AM: Laparoscopic pyeloplasty: current status. *BJU Int* 2005; 95:102.
 16. Kaouk et al, 2008. Kaouk JH, Hafron J, Parekattil S, et al: Is retroperitoneal approach feasible for robotic dismembered pyeloplasty: initial experience and long-term results. *J Endourol* 2008; 22:2153.
 17. Link, Bhayani, Kavoussi, 2006. Link RE, Bhayani SB, Kavoussi LR: A prospective comparison of robotic and laparoscopic pyeloplasty. *Ann Surg* 2006; 243:486.
 18. DiMarco et al, 2006. DiMarco DS, Gettman MT, McGee SM, et al: Long-term success of antegrade endopyelotomy compared with pyeloplasty at a single institution. *J Endourol* 2006; 20:707.
 19. Madi, Roberts, Wolf, 2008. Madi R, Roberts WW, Wolf Jr JS: Late failures after laparoscopic pyeloplasty. *Urology* 2008; 71:677.
 20. Thomas et al, 2005. Thomas JC, DeMarco RT, Donohoe JM, et al: Management of the failed pyeloplasty: a contemporary review. *J Urol* 2005; 174:2363.
 21. Varkarakis et al, 2004. Varkarakis IM, Bhayani SB, Allaf ME, et al: Management of secondary ureteropelvic junction obstruction after failed primary laparoscopic pyeloplasty. *J Urol* 2004; 172:180.
 22. Peschel, Neururer, Bartsch, Gettman, 2004. Peschel R, Neururer R, Bartsch G, Gettman MT: Robotic pyeloplasty: technique and results. *UrolClin North Am* 2004; 31:737.
 23. Bauer et al, 1999. Bauer JJ, Bishoff JT, Moore RG, et al: Laparoscopic versus open pyeloplasty: assessment of objective and subjective outcome. *J Urol* 1999; 162:692.
 24. Soulie et al, 2001. Soulie M, Salomon L, Patard JJ, et al: Extraperitoneal laparoscopic pyeloplasty: a multicenter study of 55 procedures. *J Urol* 2001; 166:48.